

The Role of the Vascular Laboratory in the Diagnosis of Renal and Mesenteric Artery Disease

Michael R. Jaff, DO, RPVI
Professor of Medicine
Harvard Medical School (Leave of Absence)
Chief Medical Officer
Boston Scientific Corporation

Michael R. Jaff, D.O. Conflicts of Interest

Part-Time Employee

Boston Scientific
Corporation

Consultant

Gilde Healthcare

Equity Shareholder

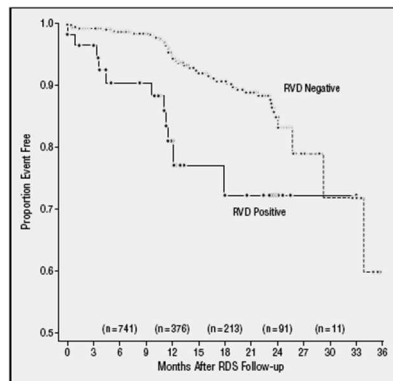
Access Vascular
Boston Scientific
Efemoral
Embolitech
Gemini
Primacea
PQ Bypass
Janacare
R3 Vascular
Vactronix
Venarum
Vascular Therapies

April 2021

There is Little Controversy Surrounding Renal Artery Stent Revascularization

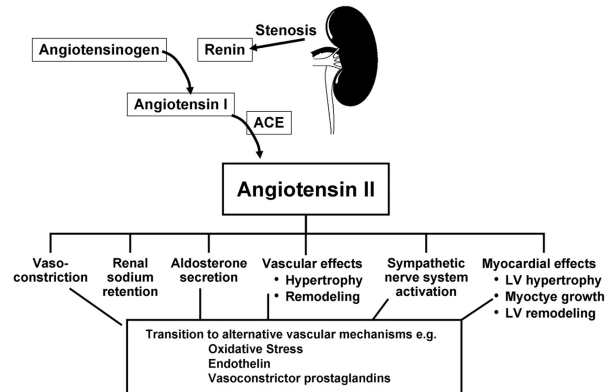
- Randomized trials demonstrated *failure* of renal artery revascularization
- There is no apparent added benefit to revascularization over optimal medical therapy alone
- The need for renal revascularization is relatively sparse
- However....

We All Accept That Atherosclerotic RAS Is Bad...



Arch Intern Med. 2005;165:207

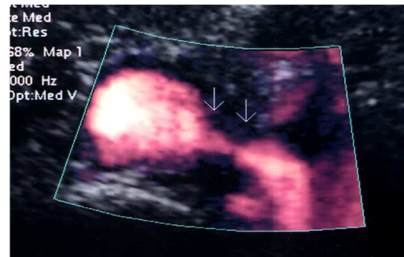
The Mechanisms of Renovascular Hypertension Have Been Well Described



Garovic, VD, et al. *Circulation*. 2005;112:1362-1374

Renal Artery Duplex Ultrasonography—At Least the Diagnosis is Non-Controversial!

- Important, valuable, non-invasive method to determine presence and severity of renal artery stenosis
- If committed, study can be mastered and results are reproducible
- Must recognize the steep learning curve



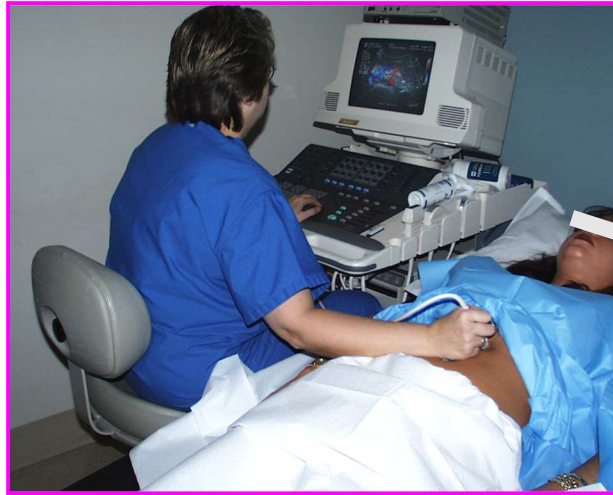Renal Artery Duplex Ultrasonography Examination Technique

- Perform examinations in the early morning after overnight fast
- May add use of Simethicone containing products
- Must have high quality color duplex ultrasound scanner with appropriate software
- Ultrasound Transducer
 - 2.25-3.5 MHz pulsed--Mechanical Sector, Phased, Curved Linear

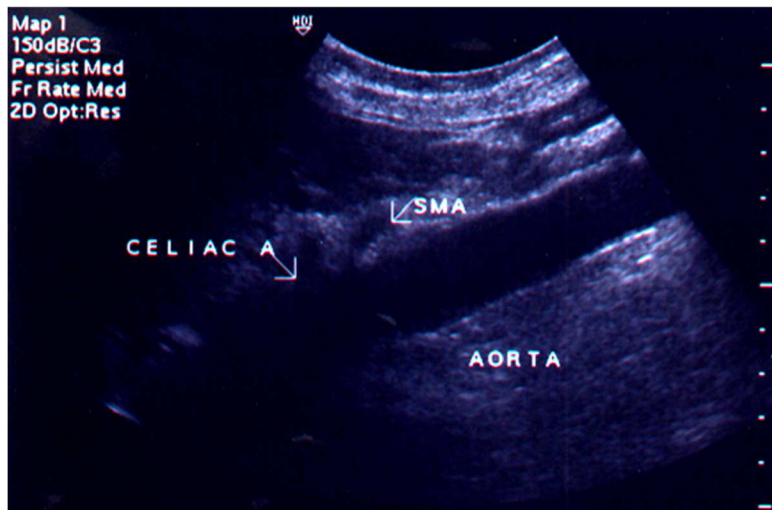
Renal Artery Duplex Ultrasonography

- **Study Initiation:**
 - Supine Position with Head Slightly Elevated
 - Probe oriented in midline, sub-xiphoid, longitudinal orientation
- Image Aorta and identify Celiac, Superior Mesenteric Arteries (SMA)
- Place Doppler Sample Volume in aorta at level of SMA--obtain Peak Systolic Velocity (PSV) at 60-degree angle

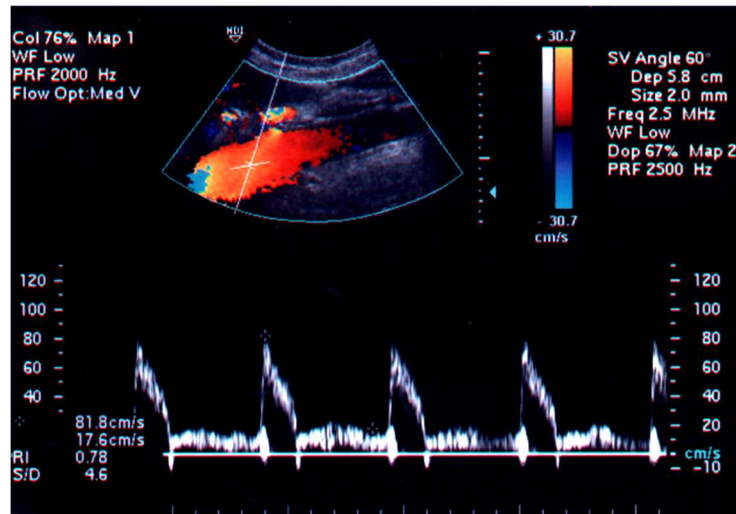
Renal Artery Duplex Ultrasonography



Gray Scale Image of Abdominal Aorta



Aortic Peak Systolic Velocity



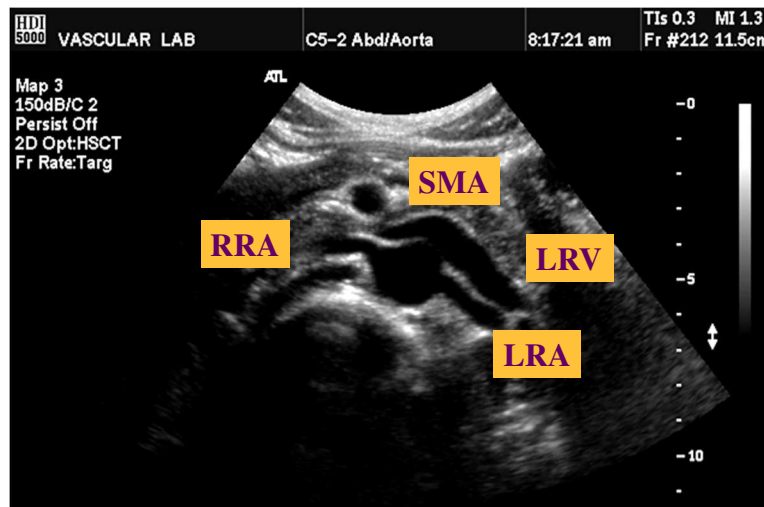
Renal Artery Duplex Ultrasonography

- This PSV within the aorta at level of SMA will be used as the DENOMINATOR for the **RENAL TO AORTIC RATIO (RAR)**
- Only valid if Aortic Velocity >40, <100 cm/sec
 - If <40 cm/sec, likely associated with ectasia/aneurysm
 - If >100 cm/sec, likely associated with atherosclerosis/stenosis

Renal Artery Duplex Ultrasonography

- Orient transducer in TRANSVERSE position
 - Identify SMA arising *anterior* from the aorta
 - Identify LEFT Renal Vein crossing *anterior* to the aorta (~80% of cases)
- **THESE ARE KEY LANDMARKS TO IDENTIFY PRIOR TO IMAGING RENAL ARTERIES!**

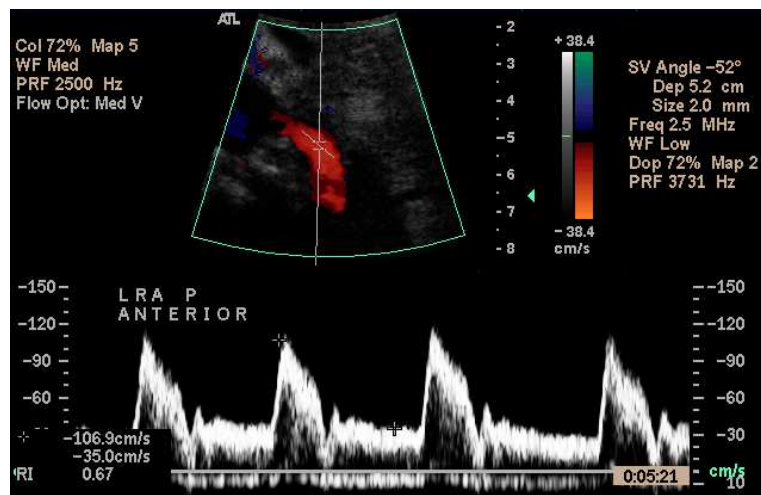
Key Landmarks for Renal Artery Duplex Ultrasonography



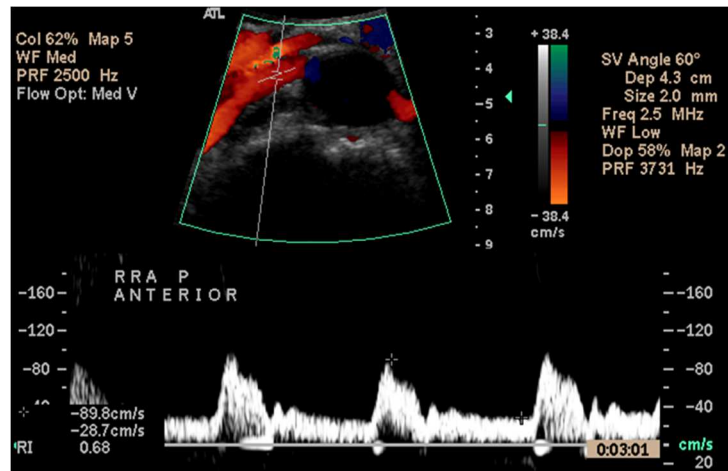
Renal Artery Duplex Ultrasonography

- Move Doppler sample volume *posterolaterally* to identify the LEFT Renal Artery
 - Classic LOW RESISTANCE Doppler waveform
 - Increased Diastolic flow
- RIGHT Renal Artery arises cephalad to Left Renal Artery
- May need to INCREASE sample volume size
 - Spectral Broadening is not relevant in visceral vascular DUS examinations
- Obtain Doppler Velocities in Origin, Proximal, Mid, Distal Vessel
 - 'Walk' Doppler sample volume from Aorta into Renal artery
- All Doppler Angles Must Be ≤ 60 -degrees

Left Renal Artery



Right Renal Artery



Renal Artery Duplex Ultrasonography

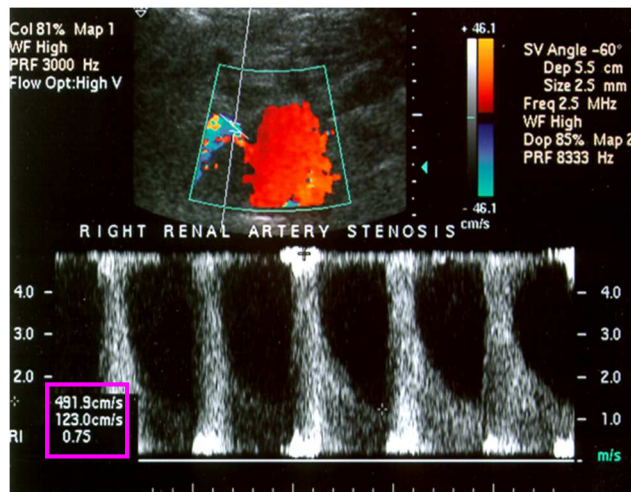
- **Criteria for $\geq 60\%$ Renal Artery Stenosis**
 - RAR ≥ 3.5
 - PSV ≥ 200 cm/sec
 - Post-stenotic Turbulence
 - Resistive Index ≤ 80 (?predictive response to intervention)
 - ? Abnormal Renal Artery Hilar Waveform

The diagnosis of hemodynamically significant renal artery stenosis ($\geq 60\%$)^(1,2,6)

- peak systolic velocity (PSV) ≥ 2.0 m/s
- end-diastolic velocity (EDV) ≥ 1.5 m/s
- RAR ≥ 3.5
- acceleration time (AT) ≥ 0.08 s
- acceleration index (AI) < 3 m/s²
- RI difference > 0.05 (stenosis occurs when there is lower RI value)
- difference in the size of the kidneys > 15 mm

J Ultrasonography 2018;18:338-43

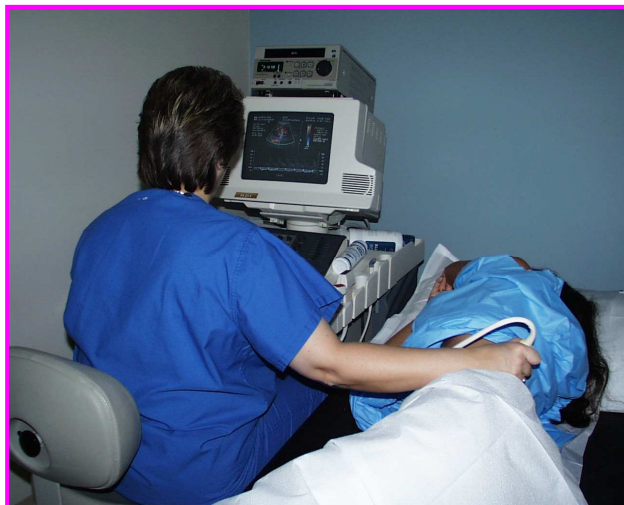Renal Artery Duplex Ultrasonography—
Renal Artery Stenosis



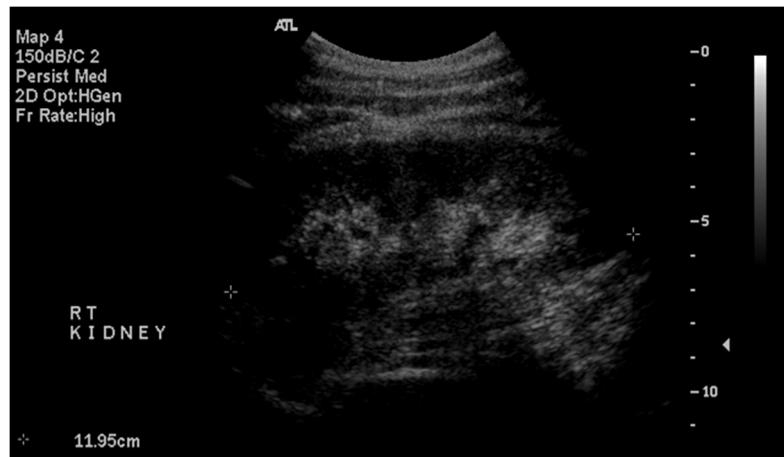Kidney Imaging

- Turn patient in lateral decubitus position
- Identify kidney in longitudinal plane
- Measure pole-to-pole length (obtain three measurements)
- Identify any cortical thinning, cysts, masses

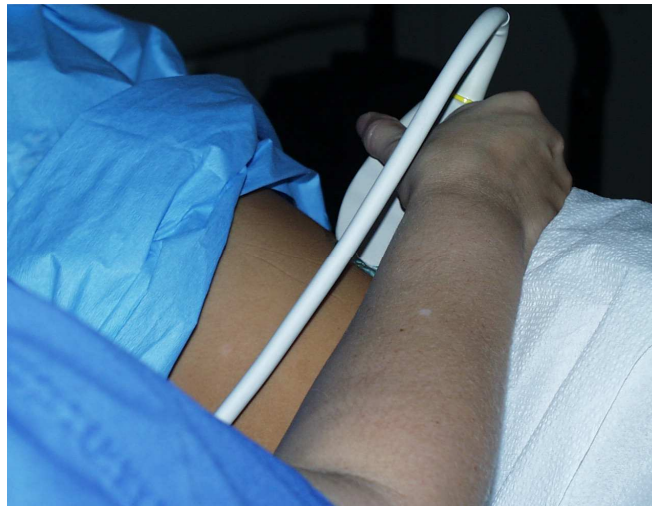
Renal Artery Duplex Ultrasonography—
Lateral Decubitus Position



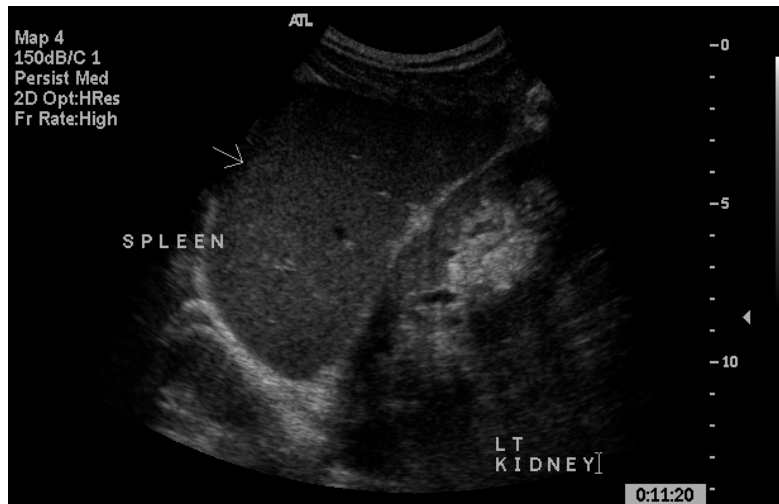
Kidney Imaging



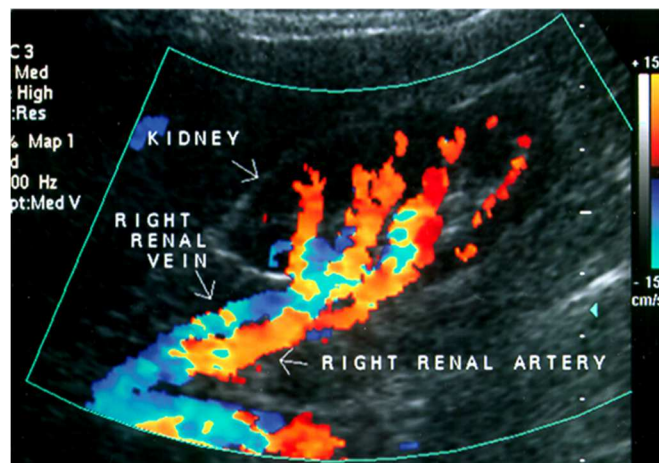
Renal Artery Duplex Ultrasonography



Know Your Acoustic Windows



Renal Artery Duplex Ultrasonography: Lateral Decubitus View



Renal Artery Duplex Ultrasonography

- Renal Artery Occlusion
 - Absence of Doppler signal in imaged renal artery
 - Patent renal vein is helpful
 - Low Amplitude, Low Velocity waveform from renal medulla, cortex
 - ? Small (<8 cm) kidney
 - Look for Accessory Renal Arteries, Collateral vessels ('Power' Doppler)

Renal Artery Duplex Ultrasonography

- 102 patients (44 men, 58 women)
- Duplex Ultrasonography and Arteriography within 1 month
- Indications
 - Difficult to control hypertension
 - Unexplained azotemia
 - Associated peripheral vascular disease
- PSV, EDV, RAR, RI, Renal Size

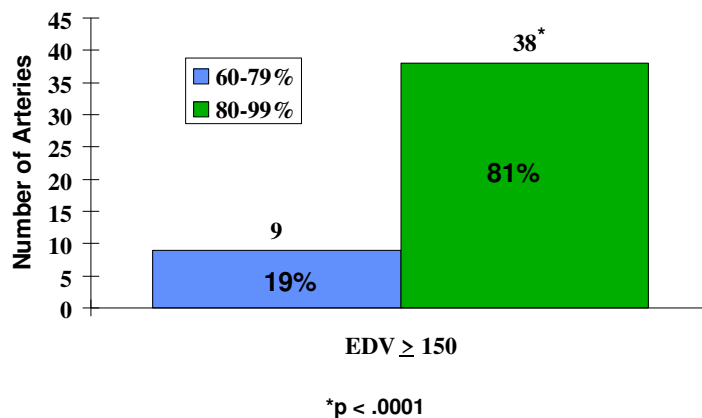
COMPARISON OF DUPLEX ULTRASOUND WITH ARTERIOGRAPHY

<u>Ultrasound</u>	<u>% Stenosis by Arteriogram</u>				<i>Total</i>
	<i>0-59</i>	<i>60-79</i>	<i>80-99</i>	<i>100</i>	
<i>0-59</i>	62	0	1	1	64
<i>60-99</i>	1	31	67	0	99
<i>100</i>	0	1	1	22	24
<i>Total</i>	63	32	69	23	187

Sensitivity	0.98	Positive Predictive Value	0.99
Specificity	0.98	Negative Predictive Value	0.97

From Olin JW et al, Ann Intern Med 1995;122:833-8

END DIASTOLIC VELOCITY (EDV) & DEGREE OF RENAL ARTERY STENOSIS

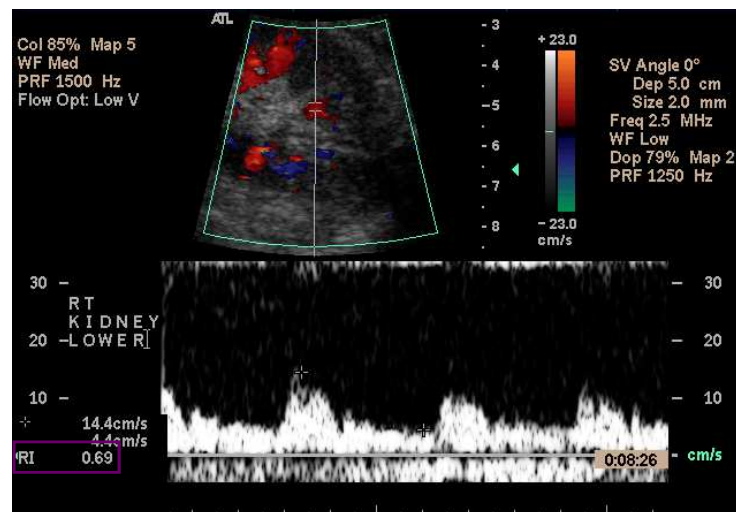


From Olin JW et al, Ann Intern Med 1995;122:833-8

Renal Resistive Index

- Obtain two medullary Doppler waveforms
 - 0-degree Doppler angle
 - Large sample volume
- Software calculates RRI

Renal Resistive Index



Duplex Ultrasonography Predicts Outcome of Therapy in Renal Artery Stenosis

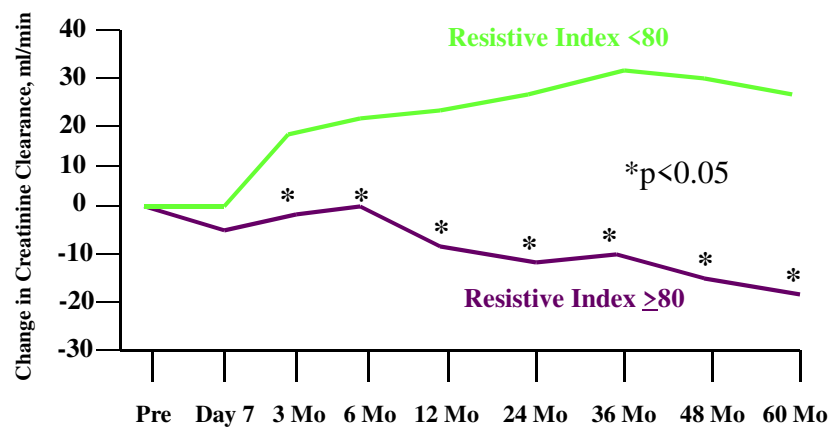
- 5950 patients with hypertension evaluated for RAS by Duplex US
- Measured Resistive Index in Renal Arterioles

$$\left[1 - \left(\frac{EDV}{PSV} \right) \right] \times 100$$

- 138 patients with unilateral/bilateral RAS underwent PTR or Surgery
 - 95% Technical Success
- Creatinine Clearance and 24 h ABP Monitoring
 - Baseline, 3, 6, 12 months post-procedure and annually

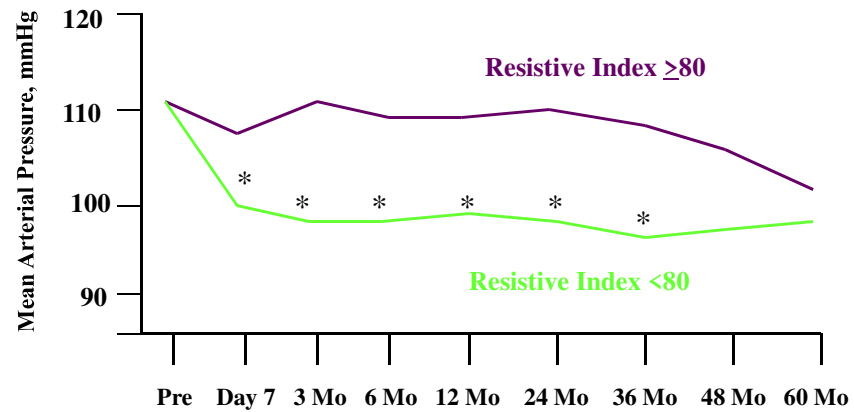
Radermacher J et al. N Engl J Med 2001;344:410-7

Duplex Ultrasonography Predicts Outcome of Therapy in Renal Artery Stenosis



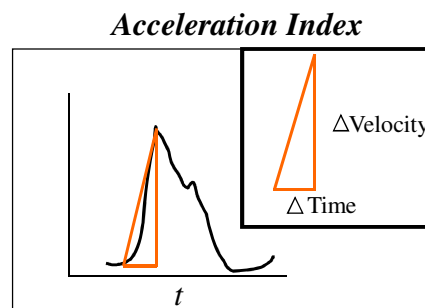
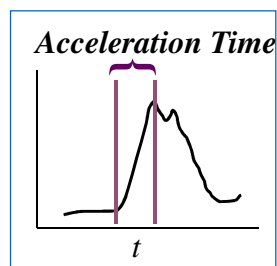
Radermacher J et al. N Engl J Med 2001;344:410-7

Duplex Ultrasonography Predicts Outcome of Therapy in Renal Artery Stenosis



Radermacher J et al. N Engl J Med 2001;344:410-7

Renal Hilar Velocity Waveforms



$AT \geq 100$ msec OR $AI < 291$ cm/sec² consistent with ≥ 60 % DR

Renal Hilar Velocity Waveforms

Hilar Parameters	Sensitivity (%)	Specificity (%)	PPV (%)	NPV (%)	Accuracy (%)
AT	67	89	56	93	85
AI	67	79	40	92	77

J Vasc Tech 1995;19:105-10

Renal Artery Duplex Ultrasonography

• **Potential Sources of Error**

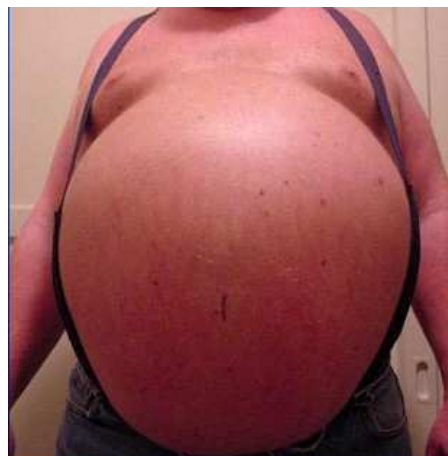- Avoid diseased aortic signal (may invalidate RAR)
- Maintain Doppler Angle 0-60 degrees
- Spectral Broadening is NOT helpful (due to large sample volume), however, post-stenotic turbulence MAY be helpful
- Make sure you are sampling renal artery (watch waveform)
- Scan the entire artery

Renal Artery Duplex Ultrasonography

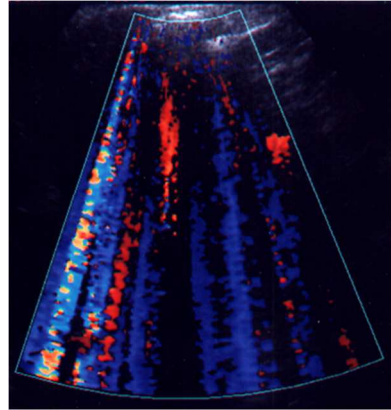
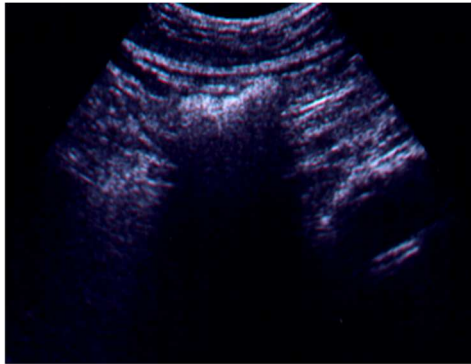
- **Limitations**

- Difficult Body Habitus
- Overlying Bowel Gas
- Anatomic Variants
 - Accessory Renal Arteries
(VERY CHALLENGING)
 - Fibromuscular Dysplasia
- Significant Parenchymal Renal Disease
- Inexperience/Frustration

So, if you start on a Monday morning like this....



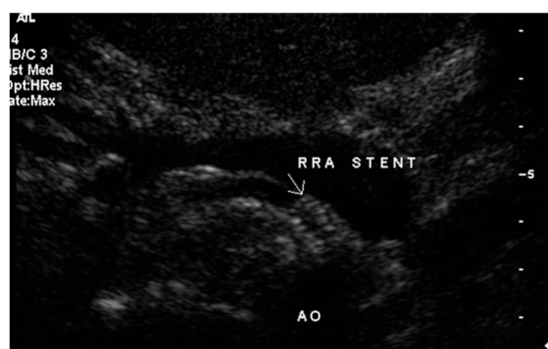Renal Artery Duplex Ultrasonography



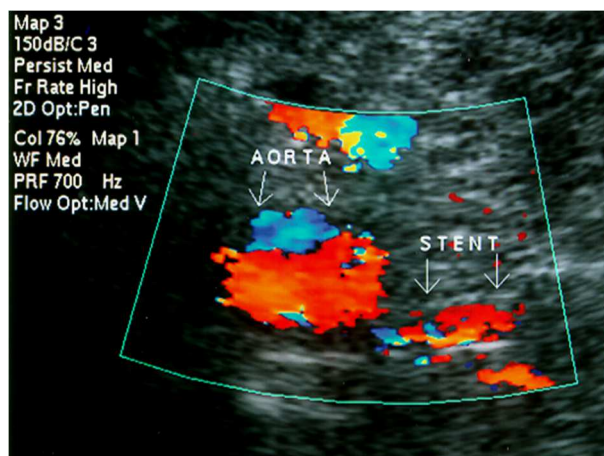
Renal Artery Stent

- Restenosis rates 15-20% at 9-12 months
- Duplex US most reliable method of assessing in-stent restenosis
- Reliable stent duplex criteria exist...

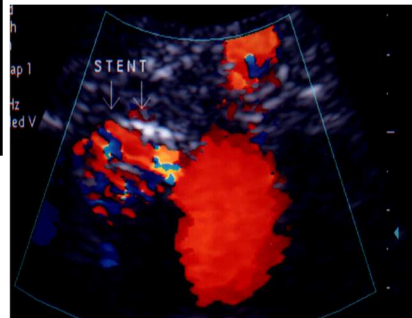
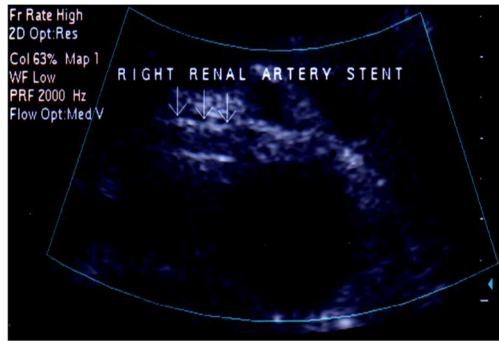
Renal Artery Stent Duplex Ultrasonography



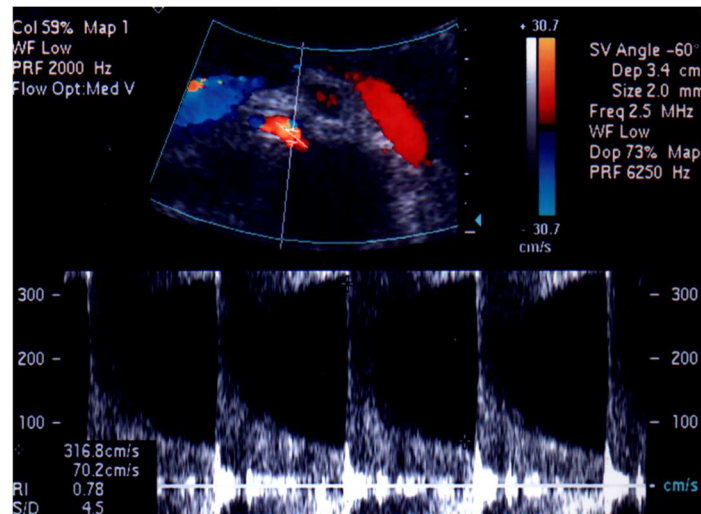
Renal Artery Stent Duplex Ultrasonography



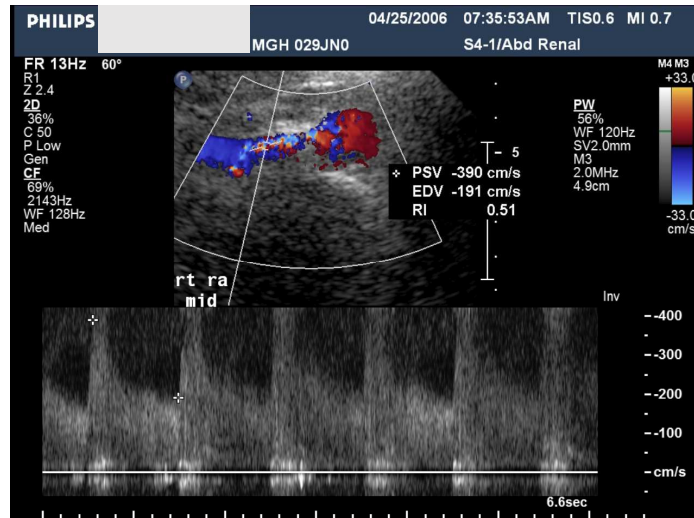
Can You Think of a Better Non-Invasive Method of Studying a Renal Artery Stent?



Persistent Ostial Right Renal Artery Stenosis--The Stent Missed!



Renal In-Stent Restenosis



The Society for Vascular Surgery practice guidelines on follow-up after vascular surgery arterial procedures



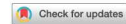R. Eugene Zierler, MD,³ William D. Jordan, MD,³ Brajesh K. Lal, MD,⁶ Firas Mussa, MD,⁴ Steven Leers, MD,⁸ Joseph Fulton, MD,¹ William Pevec, MD,⁹ Andrew Hill, MD,¹¹ and M. Hassan Murad, MD, MPH,¹ Seattle, Wash; Atlanta, Ga; Baltimore, Md; Columbia, SC; Pittsburgh, Pa; Poughkeepsie, NY; Sacramento, Calif; Ottawa, Ontario, Canada; and Rochester, Minn

Rates of Restenosis After RASR

Reference	No. ^a	% with restenosis at follow-up, months							
		6	9	12	18	24	36	60	72
Lewis, ²⁰ 1994	18			38					
Donax, ²¹ 1995	92			25					
Hadjil, ²² 1997	44			25					
White, ²³ 1997	80			19					
Rundback, ²⁴ 1998	28			25					
Rocha-Singh, ²⁵ 1999	180			12					
Rodriguez-Lopez, ²⁶ 1999	96						26		
Henry, ²⁷ 1999	259							21	
Van de Ven, ²⁸ 1999	13			25					
Yutan, ²⁹ 2001	86							37	
Ahmadi, ³⁰ 2002	32			6		6			36
Sivamurthy, ³¹ 2004	183							30	
Nolan, ³² 2005	96			25					
Muller-Hulsbeck, ³³ 2005	50		13		25				
Sapoval, ³⁴ 2005	52		14						
Sahin, ³⁵ 2006	15		0	8		31			
Rastan, ³⁶ 2008	55			4					
Rocha-Singh, ³⁷ 2008	117			21					
Khanani, ³⁸ 2008	14			0			10		
Mitra, ³⁹ 2008 (drug-eluting stents)	16			22		32			
Mitra, ³⁹ 2008 (bare-metal stents)	9			42		53			
Corriere, ⁴⁰ 2009	101	50		60					
Davies, ⁴¹ 2009	619							19	
Thalhammer, ⁴² 2010	105		17						
Latal, ⁴³ 2010	188			13					
Jaff, ⁴⁴ 2012	241		10						
Simone, ⁴⁵ 2013	216			16			59		

^aNumber of renal arteries.

The Society for Vascular Surgery practice guidelines on follow-up after vascular surgery arterial procedures



R. Eugene Zierler, MD,^a William D. Jordan, MD,^b Brajesh K. Lal, MD,^c Firas Mussa, MD,^d Steven Leers, MD,^e Joseph Fulton, MD,^f William Pevec, MD,^g Andrew Hill, MD,^h and M. Hassan Murad, MD, MPH,ⁱ Seattle, Wash; Atlanta, Ga; Baltimore, Md; Columbia, SC; Pittsburgh, Pa; Poughkeepsie, NY; Sacramento, Calif; Ottawa, Ontario, Canada; and Rochester, Minn

DUS Criteria for RA ISR

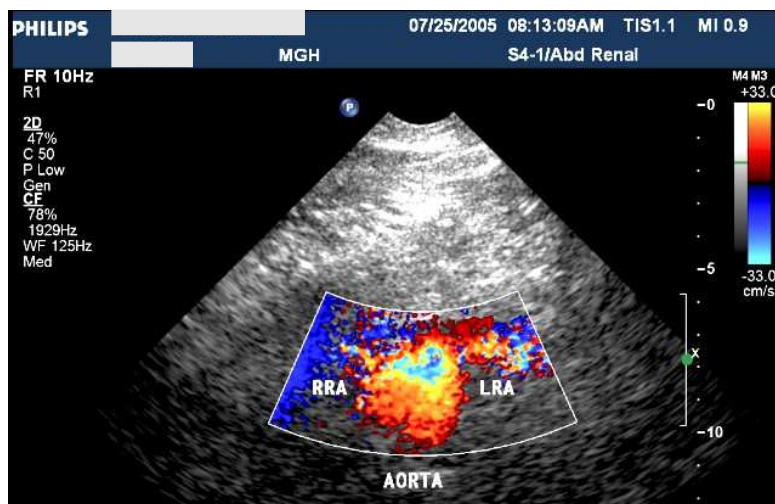
Reference	No. ^a	ISR, % diameter reduction	Renal artery PSV, cm/s	RAR
Bakker, ²⁵⁵ 1999	9	>50	226	2.7
Chi, ³⁴¹ 2009	67	>70	395	5.1
Mohabbat, ²⁵⁶ 2009 ^b	518	>60	280	4.5
Fleming, ²⁵⁷ 2010	30	>60	250	
Del Conde, ²⁵⁸ 2013	132	>60	296	4.4

PSV, Peak systolic velocity; RAR, renal to aortic velocity ratio.
^aNumber of arteries.
^bRenal artery stents and stent grafts inserted during endovascular aortic reconstruction.

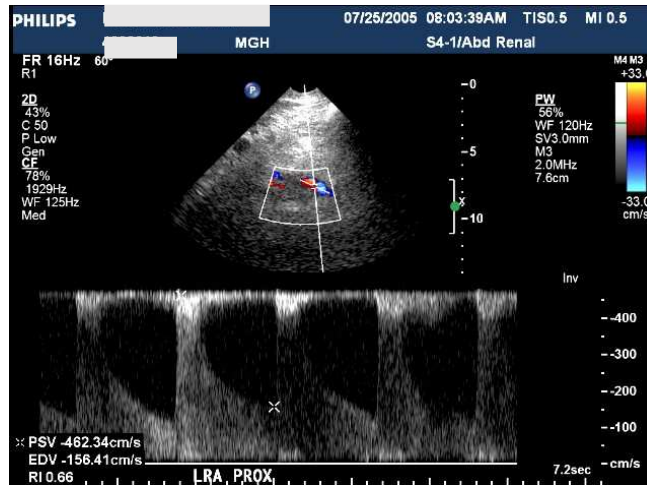- When to Survey Following RASR?
 - 1, 6, 12 months post-intervention
 - Progressive increase in PSVR, RAR

J Vasc Surg 2018;68:256-84

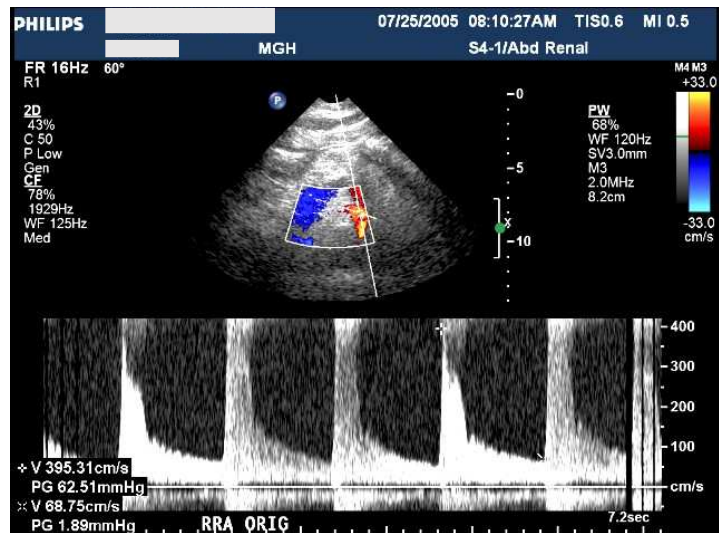
42 year old WM with 6 Drug HTN



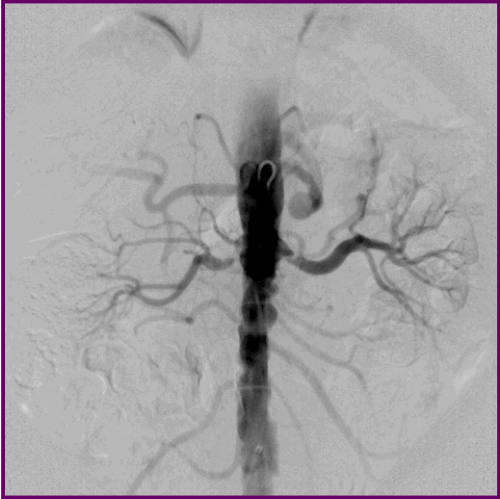
42 year old WM with 6 Drug HTN



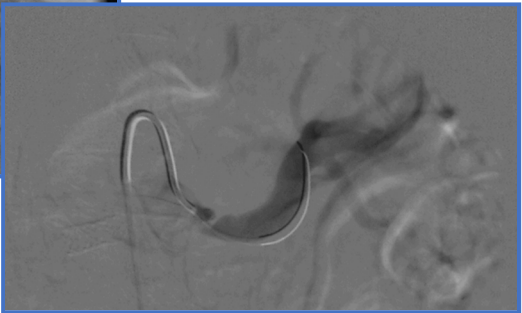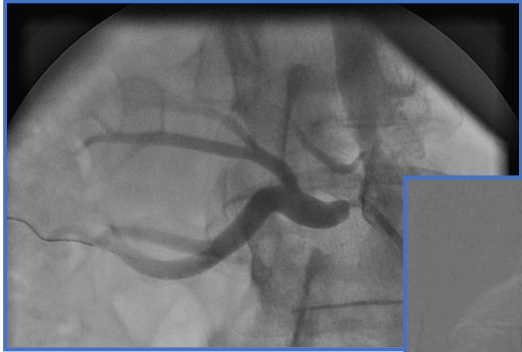
42 year old WM with 6 Drug HTN



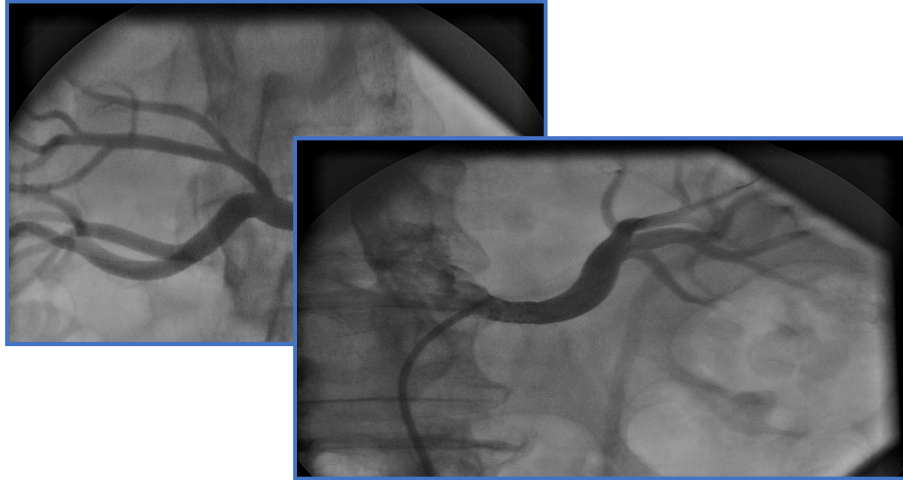
Angiography



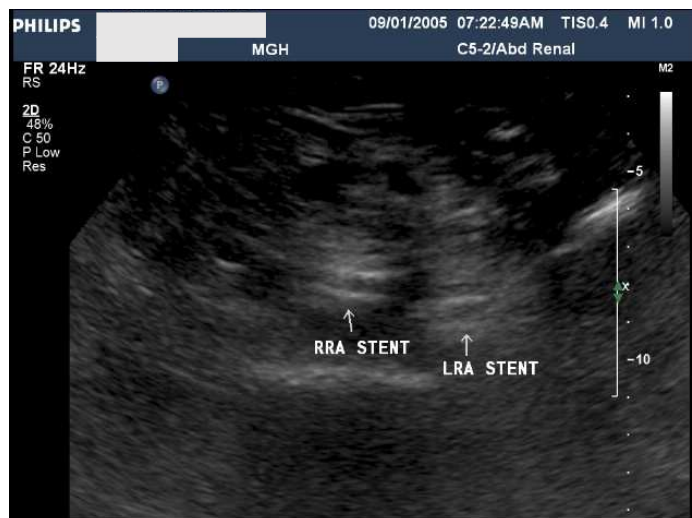Angiography



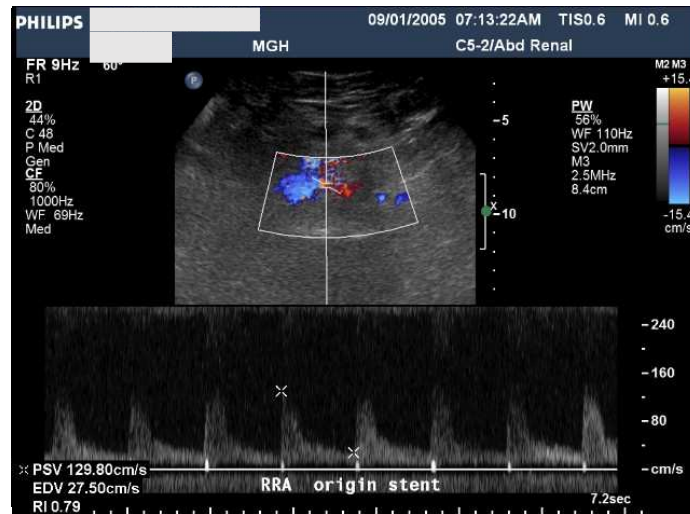Post-Intervention Angiography



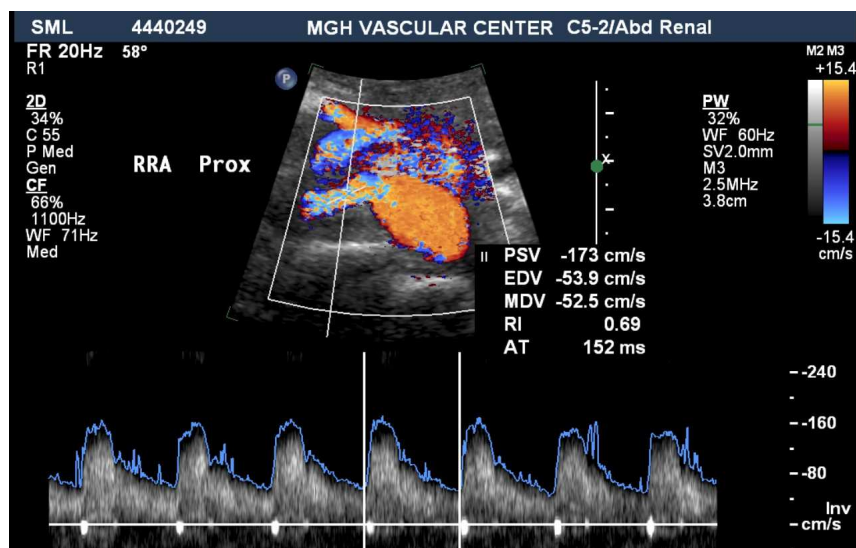
1 Month Post-Bilateral Stents



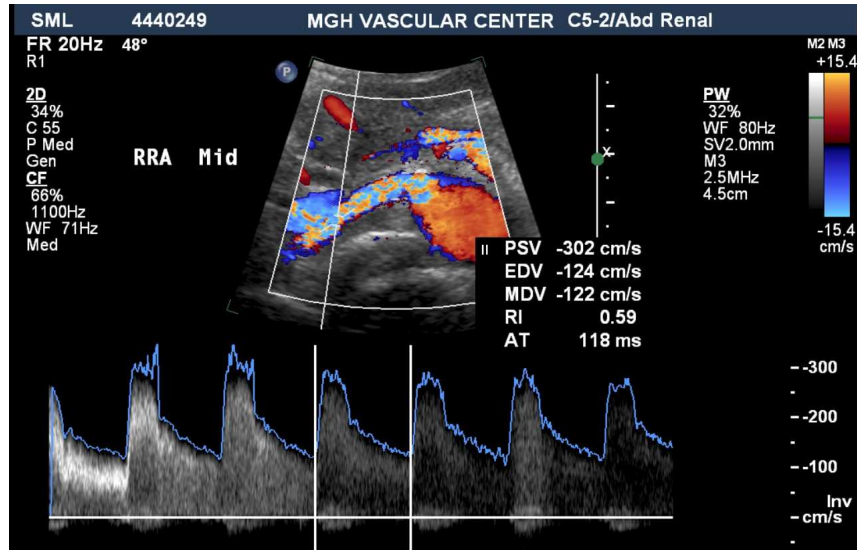
One Month Post Bilateral Stents



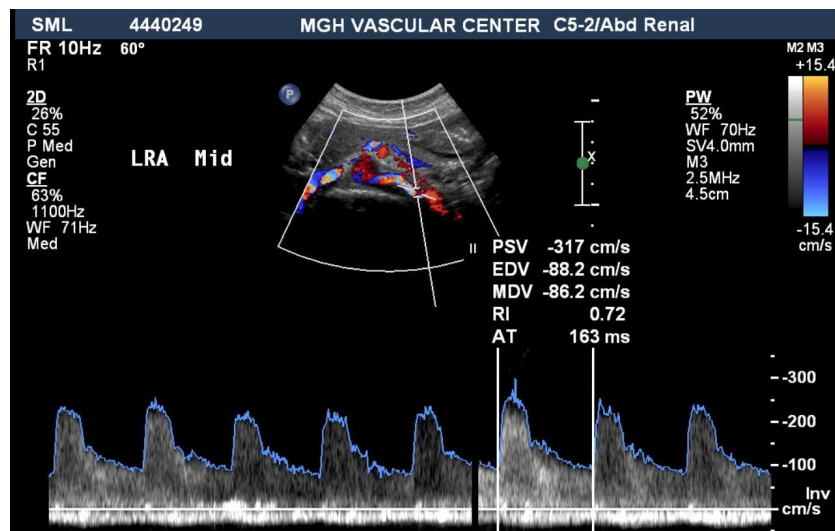
What is This?



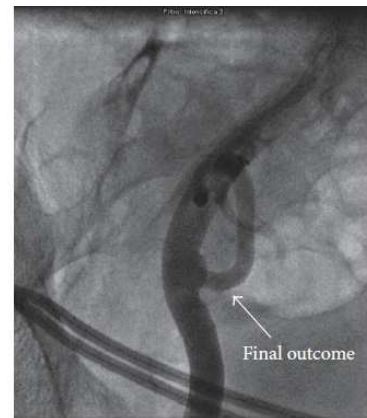
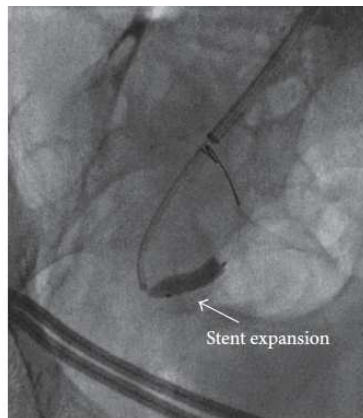
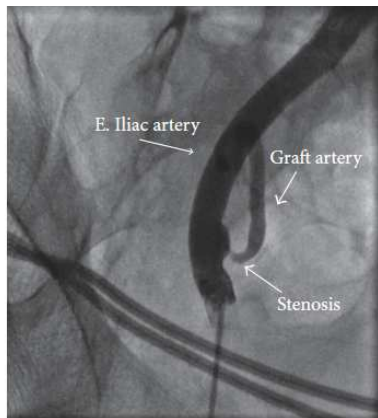
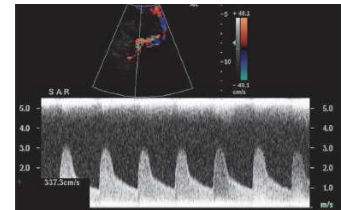
What is This?



What is This?



Transplant Renal Artery Stenosis



Biomed Res International 2018;

Transplant RAS Duplex Criteria

	Prestenting (n = 52)	Poststenting (n = 52)	p value
<i>Systolic peak velocity (SPV) at the level of TRAS (m/sec) (median, IQR)</i>	3,0 (2,6–3,6)	1,4 (1,2–1,7)	<0,001
<i>Resistive index (RI) at parenchymal level (n) (median, IQR)</i>	0,68 (0,62–0,73)	0,72 (0,69–0,77)	0,01
<i>Systolic blood pressure (mmHg) (median, IQR)</i>	145 (140–160)	140 (120–150)	0,1
<i>Diastolic blood pressure (mmHg) (median, IQR)</i>	85 (80–90)	80 (75–85)	0,06
<i>eGFR (ml/min/m²) (median, IQR)</i>	49 (35–56)	53 (41–63)	0,11

Biomed Res International 2018;

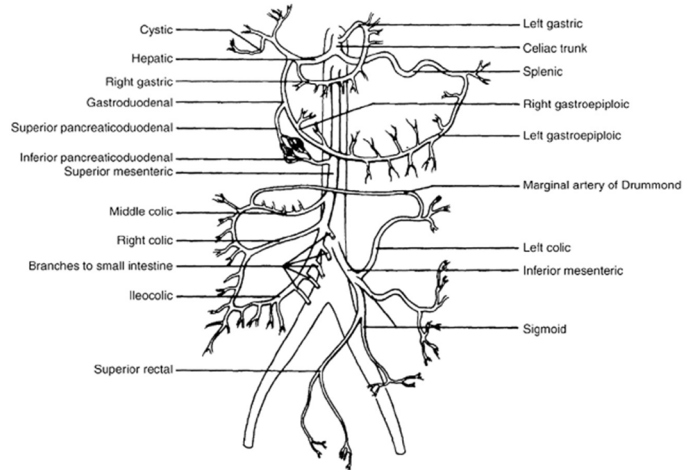
Renal Artery Duplex Ultrasonography

- Important, accurate modality to diagnose RAS and follow adequacy of revascularization
- Requires significant hands-on training
- Learning curve is steep
- ~10% of exams are inconclusive
- Ultrasound contrast agents will likely improve the accuracy and ease of RADUS

Mesenteric Artery Atherosclerosis

- Chronic mesenteric ischemia is a serious, yet difficult clinical diagnosis that is often unrecognized until serious consequences develop
- Most common etiology:
 - Atherosclerosis
 - Others:
 - Fibromuscular Dysplasia
 - Arteritis
 - SAM
 - Compression Syndrome

It's All About The Blood Flow....



Acute Mesenteric Ischemia: Etiology

- Embolization (generally to SMA): **50%**
 - If thrombus, most common from Afib. Remember to consider atheroemboli after cath procedure
- Thrombosis of an atherosclerotic plaque (generally at the vessel origin): **20%**
- Non-occlusive vessel ischemia: **20%**
- Mesenteric vein thrombosis: **10%**

Key Clinical Facts

- Classic presentation: pain out of proportion to exam & gut emptying at the onset of pain
- No specific lab finding; most frequent abnormal labs: ↑WBC in >75%, ↑lactic acidosis in >75% and amylase in >50% but
- 25% have heme + stool
- Mortality is high 50% to 80%

Diagnosis (Acute Mesenteric Ischemia): ACR Appropriateness Criteria Imaging

Radiologic Procedure	Rating	Comments	RRL*
CTA abdomen with contrast	9 YES	Fast noninvasive study that also evaluates other causes of abdominal pain.	☼☼☼
Arteriography abdomen	8	Allows diagnosis and treatment with a single procedure.	☼☼☼
X-ray abdomen	7	Initial study for patients with acute abdominal pain.	☼☼
MRA abdomen without and with contrast	7	Longer when compared to CT. Limited in distal thrombosis/embolism or nonocclusive mesenteric ischemia. See statement regarding contrast in text under "Anticipated Exceptions."	○
US abdomen	6 NO	High sensitivity and specificity for venous occlusion, and can assess other causes of abdominal pain.	○
MRA abdomen without contrast	3	Lower sensitivity and specificity than MRA that incorporates contrast.	○

Rating Scale: 1,2,3 Usually not appropriate; 4,5,6 May be appropriate; 7,8,9 Usually appropriate

***Relative Radiation Level**

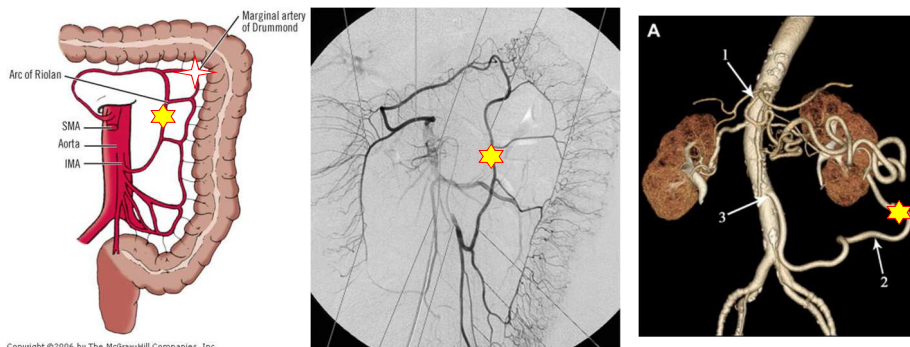
American College of Radiology (ACR) Appropriateness Criteria 2012.

Chronic Mesenteric Ischemia

- Female (70%)
- Mean age 50-60 years
- Tobacco Use
 - >75% of patients current/former
- Most patients have
 - Hypertension, CKD
- Abdominal pain induced by eating
 - Patients reduce food intake
 - Weight loss (profound)
- Majority will have atherosclerosis elsewhere
 - Coronary, Cerebrovascular

CHRONIC Mesenteric Ischemia

Multivessel Involvement "Generally" Needed Before Symptoms Develop



Copyright ©2006 by The McGraw-Hill Companies, Inc.
All rights reserved.

★ARC of Riolan Becomes "Meandering mesenteric"

★ Note: The Marginal Artery of Drummond can also be a dominant collateral bridge between the IMA and SMA

Chronic Mesenteric Ischemia Presenting Symptoms

<i>Presenting symptoms</i>	<i>No. of patients (n = 85)</i>
Abdominal pain	78 (92%)
Weight loss	74 (87%)
Diarrhea	37 (44%)
Anorexia	28 (33%)
Food fear	15 (18%)
Constipation	14 (17%)
Pain or weight loss	85 (100%)

Mateo RB, et al. J Vasc Surg. 1999;29:821-32.

Methods of Diagnosis

- Visceral Artery Duplex Ultrasonography
- Computerized Tomographic Arteriography
- (Magnetic Resonance Arteriography)
- Contrast Arteriography

ACR Appropriateness Criteria Imaging (Chronic Mesenteric Ischemia)

Radiologic Procedure	Rating	Comments	RRL*
CTA abdomen with contrast	9	Fast noninvasive study that also evaluates other causes of abdominal pain.	☼☼☼
Arteriography abdomen	7	Allows diagnosis and treatment with a single procedure.	☼☼☼
US abdomen	7	High sensitivity and specificity for venous occlusion, and can assess other causes of abdominal pain.	○
MRA abdomen without and with contrast	7	Longer when compared to CT. Limited in distal thrombosis/embolism or nonocclusive mesenteric ischemia. See statement regarding contrast in text under "Anticipated Exceptions."	○
X-ray abdomen	3	A normal examination does not exclude chronic mesenteric ischemia.	☼☼
MRA abdomen without contrast	3	Lower sensitivity and specificity than MRA that incorporates contrast.	○
Rating Scale: 1,2,3 Usually not appropriate; 4,5,6 May be appropriate; 7,8,9 Usually appropriate			*Relative Radiation Level

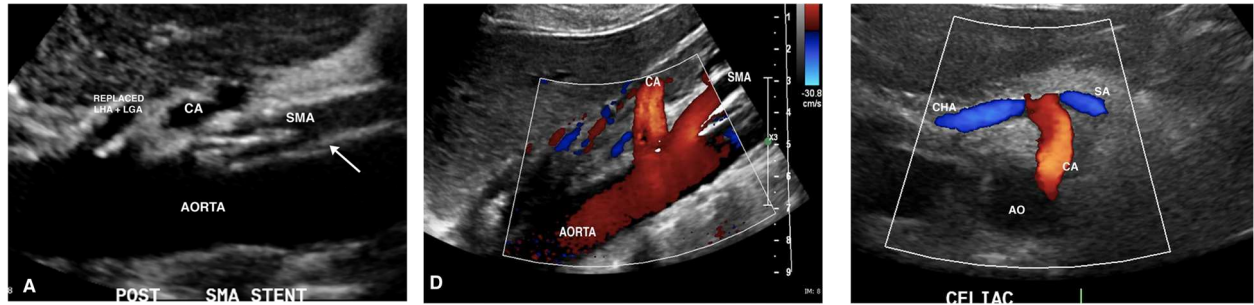
American College of Radiology (ACR) Appropriateness Criteria 2012.

Anatomic Variants in Mesenteric Artery Circulation

Normal anatomy	62–65
RHA off SMA	6–11
Accessory RHA	6–8
LHA off LGA	6.8
RHA off celiac axis	1.8
LGA directly off abdominal aorta	1.3
CHA off SMA	1.3
CHA directly off aorta	1.3
Common trunk of celiac axis and SMA, celiaco-mesenteric trunk	0.7
RHA off aorta	0.6
RHA off GDA	0.5
SMA gives rise to GDA	0.2
Splenic artery off SMA	0.2

Abdom Radiol 2020;45:2960-2979

Mesenteric Artery Duplex Ultrasonography

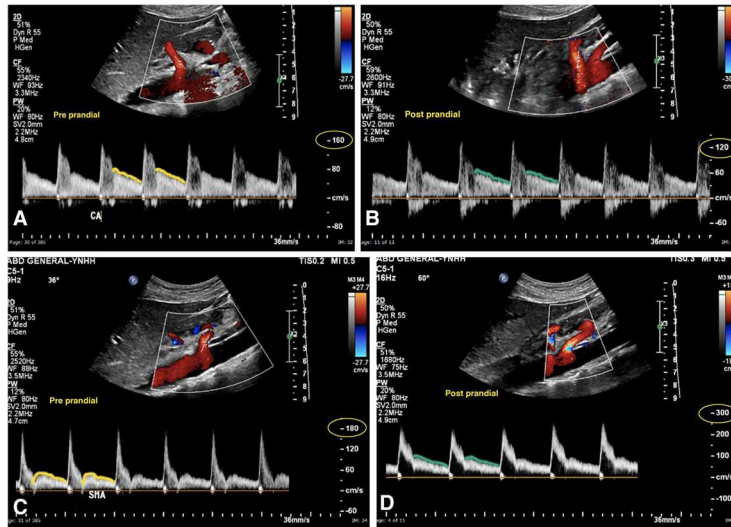


Long Axis View of Aorta

"Seagull" View

Abdom Radiol 2020;45:2960-2979

Variation in Doppler Velocities



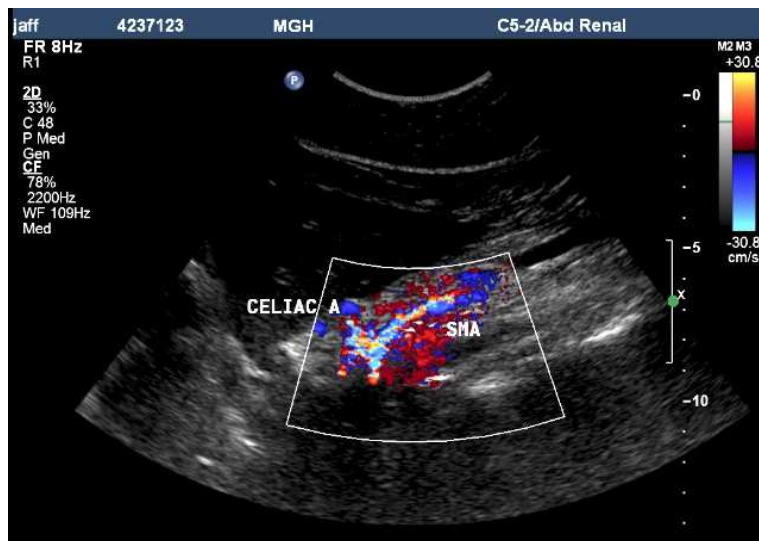
Abdom Radiol 2020;45:2960-2979

Duplex Criteria for Mesenteric Artery Stenosis

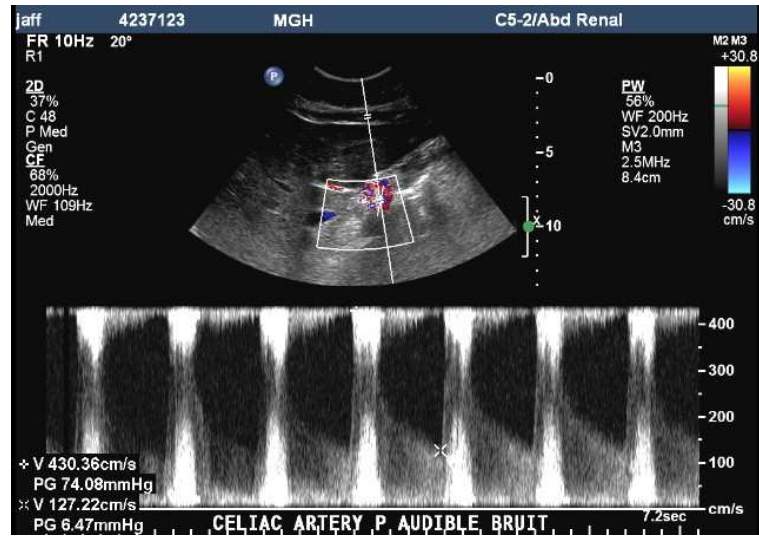
- Peak Systolic Velocity
 - Superior Mesenteric Artery >70%-- >275 cm/sec
 - Sensitivity:89-92%
 - Specificity: 92-96%
 - PPV: 80-96%
 - Celiac Artery/Inferior Mesenteric Artery >70%-- >200 cm/sec
 - Sensitivity:75-87%
 - Specificity: 80-89%
 - PPV: 63-85%
- Mesenteric:Aortic Ratio (MAR) >3.0
- Parvus et Tardus Waveform distal to stenosis

Abdom Radiol 2020;45:2960-2979

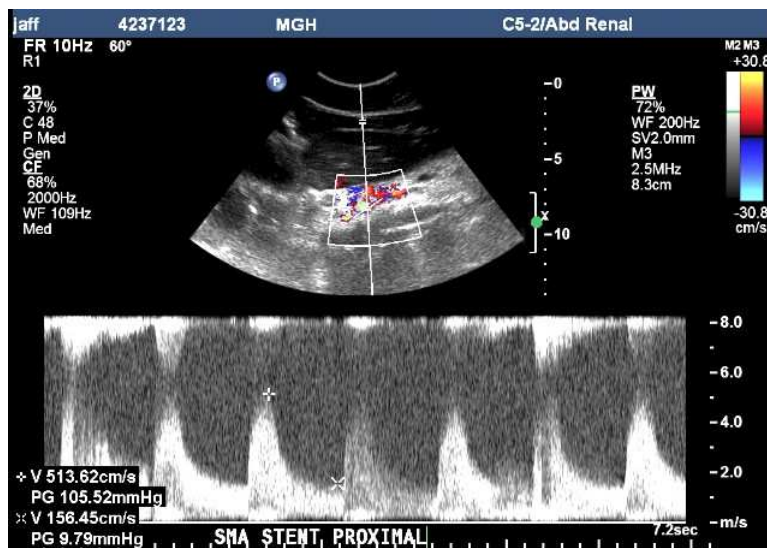86 yo Female with Abdominal Pain



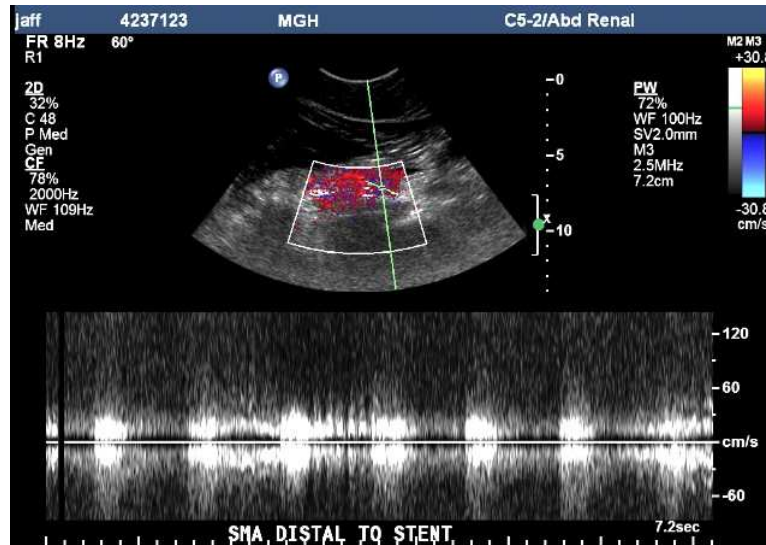Celiac Artery Doppler



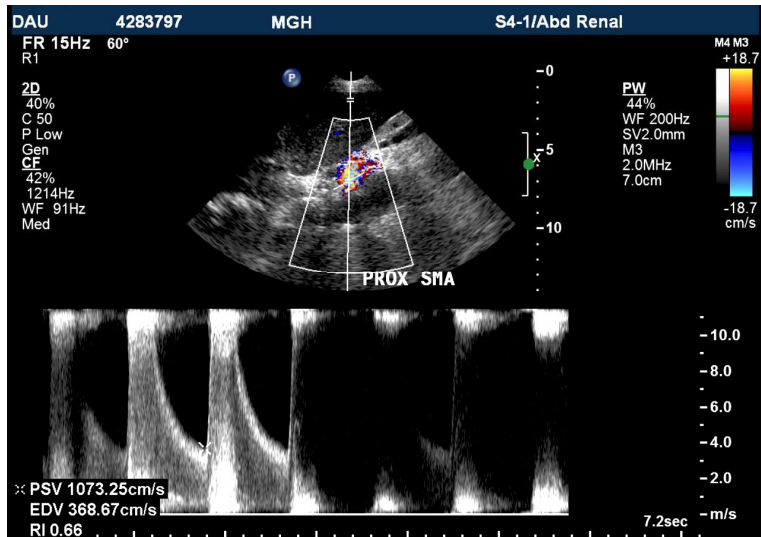
SMA Doppler



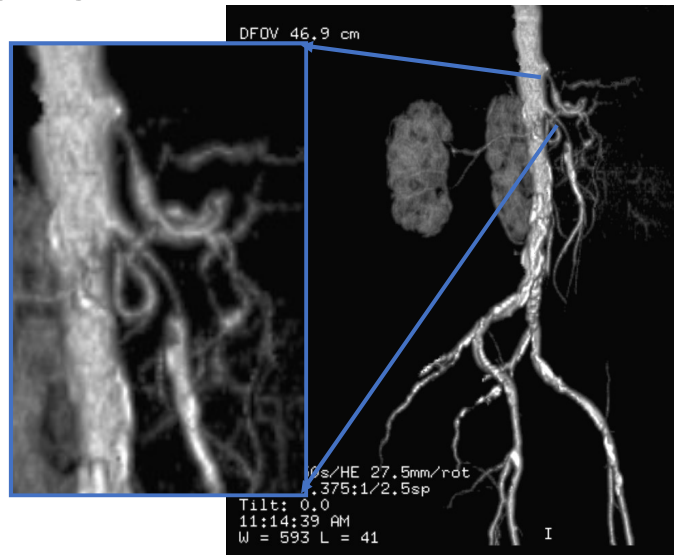
SMA Doppler



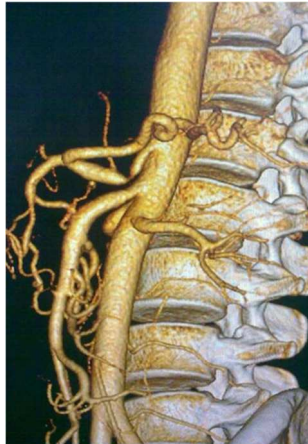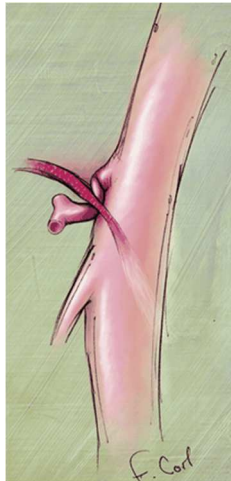SMA Duplex US



CT Angiogram

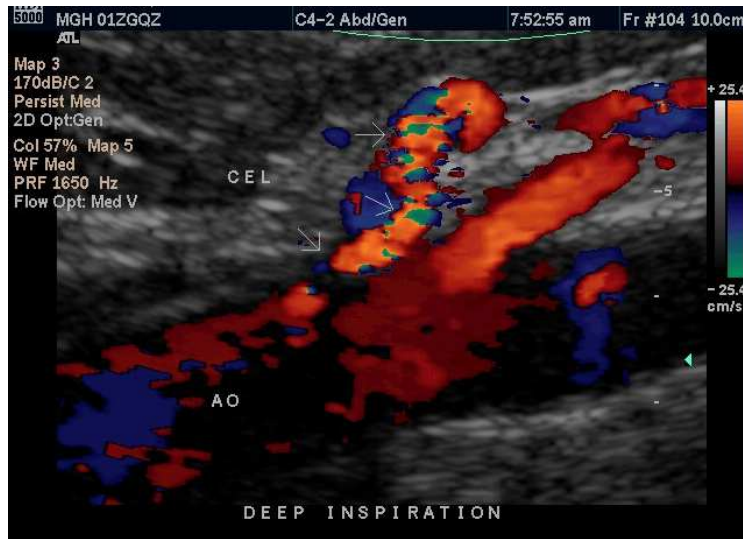


Median Arcuate Ligament Syndrome

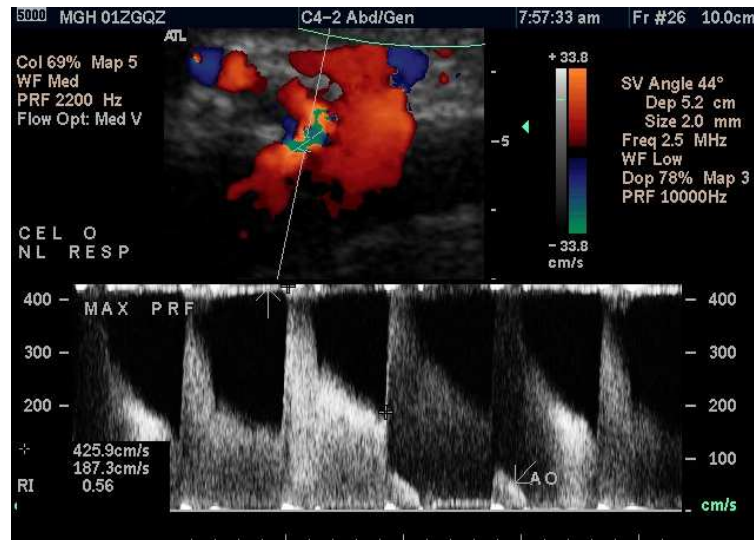


- There are hallmark angiographic and CT findings
- **Stenosis increases with expiration**
- **Stents** will be crushed and occlude so, in general, are **contraindicated**
- Symptoms from pressure on the celiac nerve plexus or ischemia?

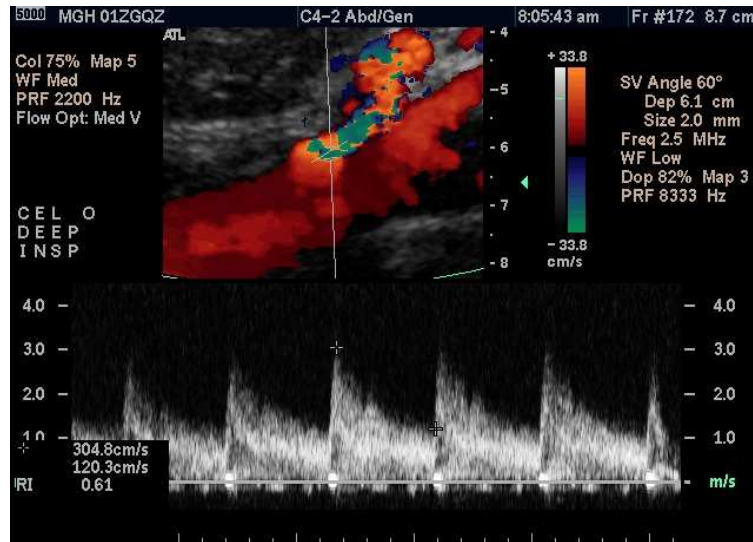
Celiac Artery Compression Syndrome



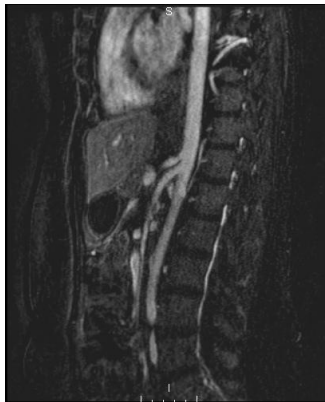Celiac Artery Compression Syndrome--Exhalation



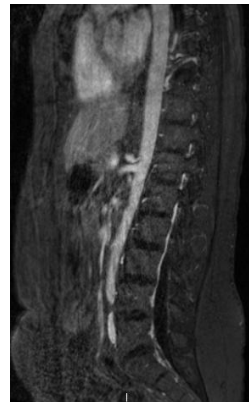Celiac Artery Compression Syndrome--Inspiration



All From the Median Arcuate Ligament...



Inspiration



Expiration

Summary

- **Visceral vascular duplex ultrasonography**

- Some of *the most challenging* vascular laboratory exams
- Steep learning curve
- Clinically meaningful and valuable
- Must provide adequate training *and* time to perform exams
- Will turn a good technologist into a great one
- Demonstrates the lab's commitment to excellence
- May provide a competitive edge