

Managing deep vein thrombosis (DVT) and venous thromboembolism (VTE) patients with duplex ultrasound

Background

A deep-vein thrombosis (DVT) is a blood clot that forms within the deep veins, usually of the leg. Deep-vein thrombosis is part of the venous thromboembolism (VTE) disorders which represent the third most common cause of death from cardiovascular disease after heart attacks and stroke. Even in patients who do not get pulmonary emboli, recurrent thrombosis and “post-thrombotic syndrome” are a major cause of morbidity.¹

VTE is a venous thrombosis causing an embolic event, mainly pulmonary embolism (PE), which will cause death in up to 30% of patients within one month of diagnosis. In fact, 25% of people afflicted may present with sudden death as the first symptom.²

In the United States alone, 600,000 new cases of DVT are diagnosed each year. It is estimated that there are more than 2.5 million diagnosed deep venous thrombosis (DVT) patients seen annually in the US.³

Presentation and assessment guidelines

Clinical presentation of a patient with DVT/VTE includes symptoms such as limb pain and limb edema, which is often unilateral but can be bilateral if the thrombus extends to the pelvic region. The limb may show a red color and be hot to the touch. The patient may complain of tenderness or even numbness in the limb. In more severe cases, a patient experiencing a pulmonary embolism event will present with shortness of breath, chest pain, and/or cough.

A review of the patient’s clinical history is critical and should focus on recent immobilization or surgery (within 3 months), stroke, limb paralysis, trauma, hospitalization, cancer, use of oral contraception, anemia/renal disorders, or a history of DVT/VTE.

The Wells and Pulmonary Embolism Rule-out (PERC) criteria may be used as a guideline to determine diagnostic and treatment protocols for each specific patient. A D-dimer assay is often performed for selected groups of patients to measure fibrin degeneration products that accumulate in the blood when thrombus is formed.

Generally speaking, D-dimer assay is not considered helpful in patients who are over 80 years old, hospitalized, pregnant, or have cancer because frequently nonspecific elevation of D-dimer levels are present.

For the majority of patients who present with DVT/VTE symptoms, venous duplex ultrasonography is the preferred choice in diagnostic imagery.⁴ Duplex ultrasound allows the operator to obtain information on the blood flow in arteries and veins, while at the same time observing the surrounding tissues. This quick and accurate assessment is key for improved patient outcomes.

DVT/VTE patient management

The following approaches may be considered based on patient history and condition:

- Anticoagulation (Oral/Systemic)
- Catheter Driven Therapy CDT (Lysis)
- Pharmaco-mechanical Therapy PMT (Extraction)
- Endovascular Stent Placement
- IVC Filter

Treatment protocols:

- Asymptomatic calf vein only DVT – repeat ultrasound in 1-2 week
- Symptomatic calf vein only DVT – Oral anticoagulation for 6-12 weeks with repeated ultrasound to follow-up on disease regression/progression. At the end of 12 weeks if disease has completely regressed no additional treatment is necessary. If disease is progressing while the patient is on oral anticoagulation, the patient should be admitted to the hospital to initiate different, more systemic, anticoagulation and work up for inherited risk factors that made him/her fail/resistive to anticoagulation
- More aggressive therapy such as Lysis and extraction can be used for patients that are/with: first episode of acute ilio-femoral DVT, symptoms for <14 days, low risk of bleeding, ambulatory with good functional capacity, and an acceptable life expectancy

Featured case study

Patient history:

A 54 year-old active male with controlled diabetes mellitus (DM), hypertension (HTN), and normal renal function was admitted to the ED with shortness of breath and right lower extremity intolerable pain and swelling for a week. Patient had O2 saturation in the 80's when admitted.

Recommendation:

Lower extremity duplex ultrasonography, transthoracic echocardiography, and chest CTA PE protocol were ordered and performed upon admission. Clinical symptoms were highly suspicious for DVT with subsequent PE. Following a standard strategy for diagnosis of PE, this patient had moderate to high clinical probability of PE. A positive and elevated D-dimer assay of 11.8 FEU indicated need for chest CTA.

A Philips EPIQ Elite⁵ premium ultrasound system with L12-3 transducer was used to perform the lower extremity duplex ultrasound.

Findings:

Duplex ultrasonography: Extensive bilateral lower extremity acute and subacute DVT was present in the distal external iliac, common femoral, femoral, and popliteal veins.

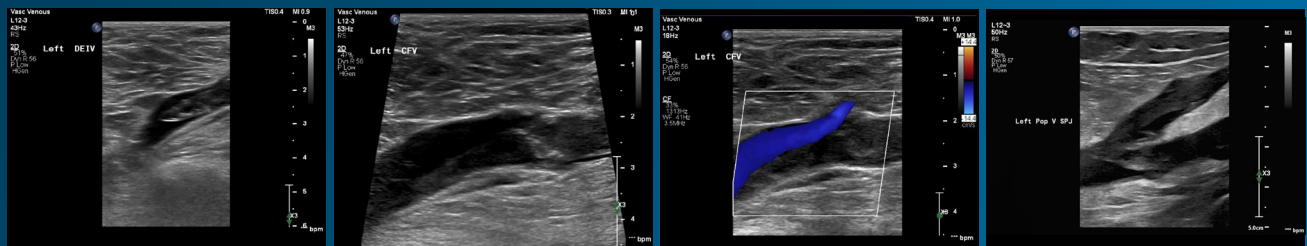
TTE: Transthoracic Echocardiography demonstrated dilated right ventricle with elevated RV/LV ratio to 1.3.

CTA PE protocol: Bilateral pulmonary embolism (PE) with significant thrombus burden and right ventricular strain.

Patient disease management:

The patient received catheter directed thrombolysis (CDT) and pharmaco-mechanical thrombectomy PMT. Since there was no risk of bleeding, the patient was placed on systemic and oral anticoagulation regimen. A follow-up pulmonary angiogram and duplex ultrasonography demonstrated patency with minimal residual of disease. As a result, no additional follow up was required for the patient.

Duplex ultrasonography findings:

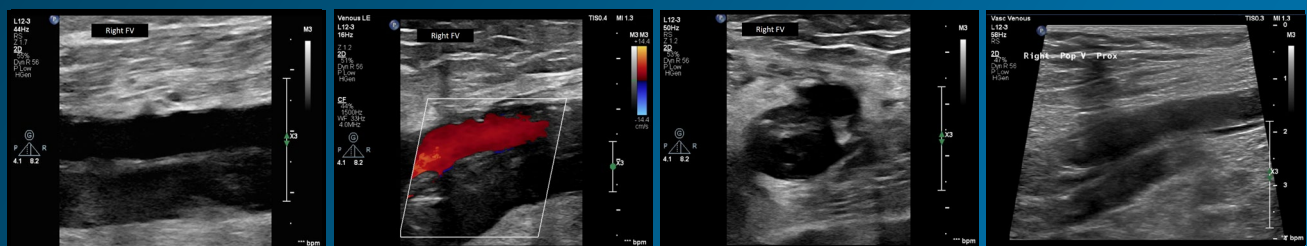


Lt external Iliac thrombus

Lt common femoral vein thrombus

Color flow near sapheno-femoral junction

Lt popliteal vein thrombus



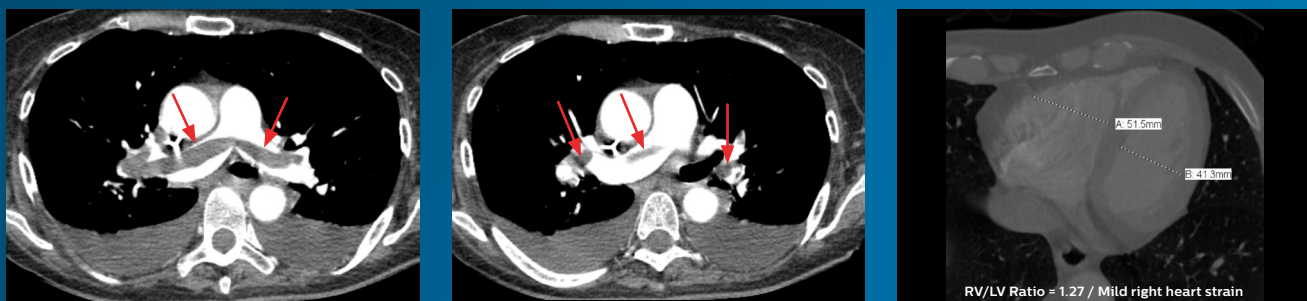Rt FV thrombus ex

Rt FV with Color ex

Rt FV Transverse ex

Rt Popliteal Vein

CT PE findings:



RV/LV Ratio = 1.27 / Mild right heart strain

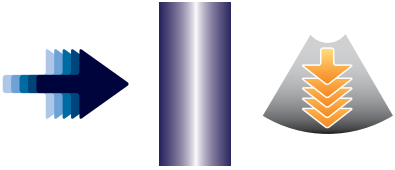
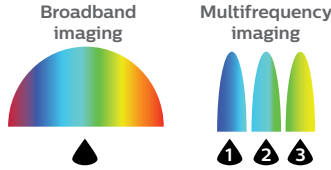

The technology perspective

The primary diagnostic modality when pulmonary embolism is suspected has been CTA PE protocol. However today, venous duplex ultrasonography plays a major role in locating where venous thrombosis originates. In the past two decades, it has virtually replaced venography as the gold standard in the diagnosis of ilio-femoral and femoro-popliteal deep venous thrombosis. Advancements in ultrasound

equipment and transducer technology allow clinicians to quickly assess patients for DVT, even in technically challenging or complex exams.

Key ultrasound solutions

The Philips EPIQ Elite premium ultrasound system has clinically tailored tools designed to elevate DVT diagnostic confidence to new levels.

nSIGHT imaging architecture 	Broadband frequency imaging 	Advanced image artifact reduction technologies 
Frame rates Focused beam Penetration	Broadband frequency imaging	SonoCT XRES Pro
<p>Multi-stage precision beamformer with massive parallel processing enables:</p> <ul style="list-style-type: none"> • Better penetration with resolution at depth • Improved focusing throughout the image to visualize superficial vessels as well as deeper veins • Improved frame rates in all imaging modes 	<p>Utilizes all available frequencies all the time to get the best penetration and resolution without compromise.</p> <ul style="list-style-type: none"> • User selectable controls for frequency in 2D and Color • Captures all frequency information for different tissue characteristics • Enhance penetration and resolution of complex flow states 	<p>SonoCT and XRES Pro help reduce many of the artifacts seen in DVT imaging including:</p> <ul style="list-style-type: none"> • Speckle artifact caused by beam scattering • Noise and clutter in difficult to see deep veins • Generalized artifacts caused by swollen limbs

Duplex ultrasonography is a highly accurate, fast, relatively inexpensive, reproducible, and safe non-ionizing tool that provides high quality images for managing DVT and VTE patients.

About the author:

Muhammad Hassan, MBBCh, RPVI, RVT, RDCS, RDMS is the Department Manager of Echocardiography and Noninvasive Vascular Testing, Miami Cardiac & Vascular Institute at Baptist Hospital of Miami, FL. He is responsible for the fiscal, clinical, and resources management of the Non-Invasive Vascular Testing Department. This includes development, operational performance, and continuous improvement of the daily operation. Muhammad supervises a team of 50 physicians, nurses, technologists, and ancillary members to ensure compliance with Baptist Health South Florida's service standards and JCAHO and IAC performance standards among other regulatory agencies.



References

- 1 Waheed, Sheikh M., Kudaravalli, Pujitha, Hotwagner, David T., *Deep Vein Thrombosis (DVT)*, NCBI Bookshelf, January 29, 2020, <https://www.ncbi.nlm.nih.gov/books/NBK507708/>, accessed August 10, 2020.
- 2 *Data and Statistics on Venous Thromboembolism*, CDC Centers for Disease Control and Prevention, <https://www.cdc.gov/ncbddd/dvt/data.html>, accessed on August 10, 2020.
- 3 *Deep Vein Thrombosis (DVT)*, Stanford Health care, <https://stanfordhealthcare.org/medical-conditions/blood-heart-circulation/deep-vein-thrombosis.html#:~:text=In%20the%20United%20States%20alone,deep%20vein%20thrombosis%20each%20year>, accessed August 10, 2020.
- 4 Cheung, Maureen E., Firstenberg, Michael S., *Duplex Ultrasound*, NCBI Bookshelf, May 12, 2020, <https://www.ncbi.nlm.nih.gov/books/NBK459266/>, accessed August 10, 2020.
- 5 www.philips.com/epiq